

Parosteal Osteosarcoma of the Orbit

Nikolaos T. Chalvatzis, M.D., Ph.D.*[†],

George Kalantzis, M.D.*,

Maria-Eleni Manthou, M.D., Ph.D.[‡],

Chris Collins, M.D., Ph.D., F.R.C.Path.§, and

Michael J. Potts, F.R.C.Ophth., Ph.D.*

Abstract: A 60-year-old woman was referred to Bristol Eye Hospital because of a progressive, painless, right proptosis. CT revealed a well-defined, hyperdense lesion adjacent to the lateral orbital wall. A marginal excision was performed. The mass was stony-hard, lobulated, and encapsulated. Histopathologic findings were consistent with a low-grade parosteal osteosarcoma. Parosteal osteosarcoma is a rare osteogenic tumor that usually affects the long bones. It represents a malignant, though well differentiated, tumor that has a relatively good prognosis after a wide excision. However, local recurrences are not rare and have been associated with dedifferentiation. The latter affects the prognosis adversely and, thus, regular follow-ups are strongly suggested after the initial tumor excision. In the present case, no further treatment was administered and

*Bristol Eye Hospital, Bristol, United Kingdom; Departments of [†]Ophthalmology and [‡]Histopathology, Aristotle University of Thessaloniki, Thessaloniki, Greece; and [§]Bristol Royal Infirmary, Bristol, United Kingdom.

Accepted for publication September 17, 2007.

There was no prior financial support and none of the contributing authors has any financial interest related to this article.

Address correspondence and reprint requests to Nikolaos T. Chalvatzis, Amorgou 27, 55337, Thessaloniki, Greece. E-mail: nikocha@hotmail.com

DOI: 10.1097/IOP.0b013e31816e410d

the patient was reported disease free 26 months after surgery.

Parosteal osteosarcoma is a rare osteogenic tumor that commonly arises from the surface of long bones. It is a well-differentiated sarcoma that displays a slow evolution with only local extent.¹⁻⁴ To the best of our knowledge, only 3 cases of similar tumors located in the orbit have been reported in the literature,^{5,6} although each case had a unique history and different evolution. We report a case of a primary parosteal osteosarcoma of the orbit in a middle-aged woman, with no previous history of trauma or surgery.

CASE REPORT

A 60-year-old woman was referred to the orbital clinic of Bristol Eye Hospital in March 2004 with a complaint of a "popped" right eye that became very obvious over the previous 2 to 3 years. Neither pain nor other symptoms were mentioned apart from diplopia in upgaze. The patient denied having previous trauma or surgery.

On ophthalmic examination, there was 5 mm of relative right proptosis. Visual acuity was 20/20 OU and optic nerve function appeared normal. No palpable mass was found and slit lamp examination was unremarkable. Orthoptic examination revealed moderate restriction in motility, affecting mostly the upgaze. An orbital mass was suspected. CT revealed a well-defined, hyperdense, lobulated tumor adjacent to the lateral orbital wall. The mass, lying extraconally and measuring 2 cm × 3 cm, seemed to cause a significant displacement of the lateral rectus muscle and the optic nerve (Fig. 1).

The patient underwent a lateral orbitotomy. Intraoperatively, the tumor was found attached to the lateral wall of the orbit, invading the lateral rectus muscle. Part of the affected muscle was sacrificed. The tumor appeared lobulated with a smooth capsule. It was extremely hard and grayish (Fig. 2A).

Histopathologic examination demonstrated a well-defined bony mass with several small, separate, peripheral nodules. The bony trabeculae were disposed in a nonstructural architecture and were composed of immature woven bone. Surface osteoblastic activity was almost completely absent. The intertrabecular space was filled with a fibroblastic stroma in which the constituent fibroblasts showed mild nuclear atypia. The findings were consistent with a low-grade parosteal osteosarcoma of the orbit (Fig. 2B).

Postoperatively, the patient had moderate, local edema, and esotropia due to the lateral rectus dysfunction. The diplopia was

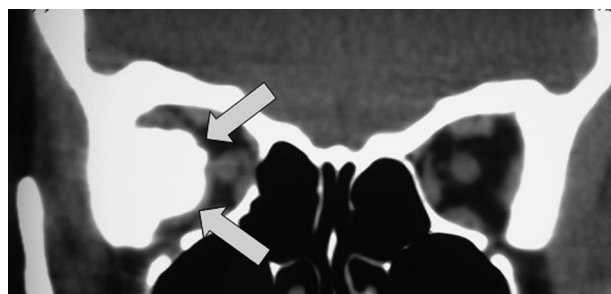


FIG. 1. Coronal T₁ CT shows a well-defined, hyperdense, lobulated lesion emerging from the lateral orbital wall (arrows).

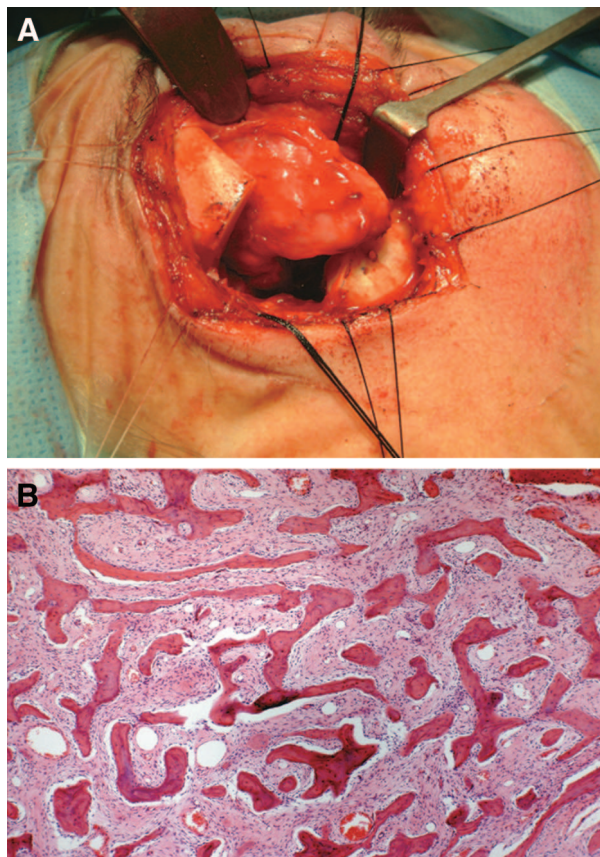


FIG. 2. **A**, Perioperatively, the tumor is easily recognizable through the lateral orbitotomy. It appeared attached to the lateral orbital wall, showing a smooth, lobulated surface. **B**, The tumor consists of a well-defined bony mass. The bony trabeculae were disposed in a nonstructural architecture and were composed of immature woven bone. The intertrabecular space was filled with a fibroblastic stroma in which the constituent fibroblasts showed mild nuclear atypia. The findings were consistent with a low-grade parosteal osteosarcoma of the orbit (hematoxylin-eosin, ×100).

temporarily managed with botulinum toxin injections; strabismus surgery was planned. The patient has been followed with repeat CT and is free of tumor 26 months after the initial excision.

DISCUSSION

Despite previous discussion on terminology, parosteal osteosarcoma is now considered a distinct clinicopathologic entity.^{1,3,4} It is a low-grade malignant tumor that primarily affects the surface of long bones, and it occurs more often in women.^{2,4,6} It usually develops slowly with minimal symptoms related mainly to the local extent of the tumor. The patient described here was a woman in her sixth decade with slowly progressive, painless proptosis. Similarly, all 3 of the previously reported orbital cases displayed a slow tumor evolution.^{5,6}

CT is useful for the diagnosis of parosteal osteosarcoma, whereby a well-circumscribed and hyperdense mass adjacent to the surface of the bone is revealed.⁷ In its periphery, the tumor may appear less opaque due to less mineralization. It has also been suggested that less opaque lesions may be associated with

higher grade or dedifferentiated tumors.^{2,6,8} MRI may reveal a suspected local soft-tissue invasion.

Gross anatomy is usually related to the radiologic findings. Parosteal osteosarcomas are typically stony hard, lobulated, and encapsulated. They occasionally invade the surrounding muscles, as in our case.

Histopathology usually confirms the diagnosis of parosteal osteosarcoma, which is typically a low-grade tumor with a hypocellular spindle-cell stroma that contains trabeculae of bone. Based on the grading system suggested by Unni and Dahlin,⁹ the majority of parosteal osteosarcomas show minimal atypia and rare mitoses and are classified as grade 1 tumors. Specimens that display more cellular pleomorphism, higher spindle-cell populations, and rare mitoses are classified as grade 2 tumors. Our case appears to be a grade 1 tumor.

Differential diagnosis should include 1) osteomas that are common in the cranium but without tendency to grow in size; 2) ossifying and cellular fibromas; 3) osteochondromas; 4) high-grade osteosarcomas, which rarely affect the orbit; and 5) myositis ossificans, which is distinguished mainly on the basis of its orderly pattern of maturation.

The concept of dedifferentiation of parosteal osteosarcomas has been well described.^{8,10} Transformation in high-grade sarcomas is strongly associated with local tumor recurrences, which often follow marginal excisions. Parmar et al.⁶ described an unusual transformation of a twice-excised orbital parosteal osteosarcoma in a liposarcoma. The prognosis of dedifferentiated parosteal osteosarcomas resembles that for patients with intramedullary osteosarcomas and in such cases treatment should include more radical excisions and/or chemotherapy. CT may provide evidence of tumor transformation by showing areas of less opaque, lytic lesions within tumors that have the typical appearance of parosteal osteosarcomas. In one of the largest studies that refer to dedifferentiation of such tumors, the mean interval between the initial surgery and tumor transformation was 153 months.⁸ This implies that 5-year survival does not indicate cure for parosteal osteosarcoma.

In contrast, Okada et al.² noted the cumulative probability of local recurrence was 26% at 5 years and 41% at 10 years. As widely accepted, tumor recurrence is less likely to occur after wide excision. Unfortunately, wide excisions are not feasible at sites where vital structures are involved, such as the orbit. Therefore, patients with orbital parosteal osteosarcoma should be followed for several years to monitor for local recurrence and possible tumor dedifferentiation.

REFERENCES

1. Geschikter C, Copeland MM. Parosteal osteoma of bone: a new entity. *Ann Surg* 1951;133:790–807.
2. Okada K, Frassica FJ, Sim FH, et al. Parosteal osteosarcoma. A clinicopathological study. *J Bone Joint Surg Am* 1994;76:366–78.
3. Ahuja SC, Villacin AB, Smith J, et al. Juxtacortical (parosteal) osteogenic sarcoma. Histological grading and prognosis. *J Bone Joint Surg Am* 1977;59:632–47.
4. Unni K, Dahlin DC, Beabout JW, Ivins JC. Parosteal osteogenic sarcoma. *Cancer* 1976;37:2466–75.
5. Marks MP, Marks SC, Segall HD, et al. Case report 420; parosteal osteosarcoma. *Skeletal Radiol* 1987;16:246–51.
6. Parmar DN, Luthert PJ, Cree IA, et al. Two unusual osteogenic orbital tumors. Presumed parosteal osteosarcomas of the orbit. *Ophthalmology* 2001;108:1452–6.
7. Kumar R, Moser RP Jr, Madewell JE, Edeiken J. Parosteal osteo-

genic sarcoma arising in cranial bones: clinical and radiologic features in eight patients. *AJR Am J Roentgenol* 1990;155:113–17.

8. Wold LE, Unni KK, Beabout JW, et al. Dedifferentiated parosteal osteosarcoma. *J Bone Joint Surg Am* 1984;66:53–9.
9. Unni KK, Dahlin DC. Grading of bone tumors. *Semin Diagn Pathol* 1984;1:165–72.
10. Sheth DS, Yasko AW, Raymond AK, et al. Conventional and dedifferentiated parosteal osteosarcoma. Diagnosis, treatment and outcome. *Cancer* 1996;78:2136–45.